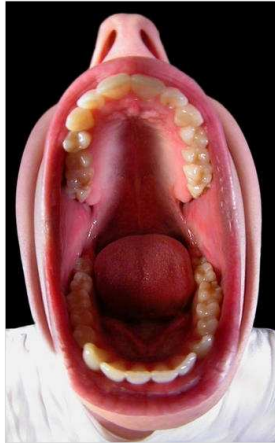
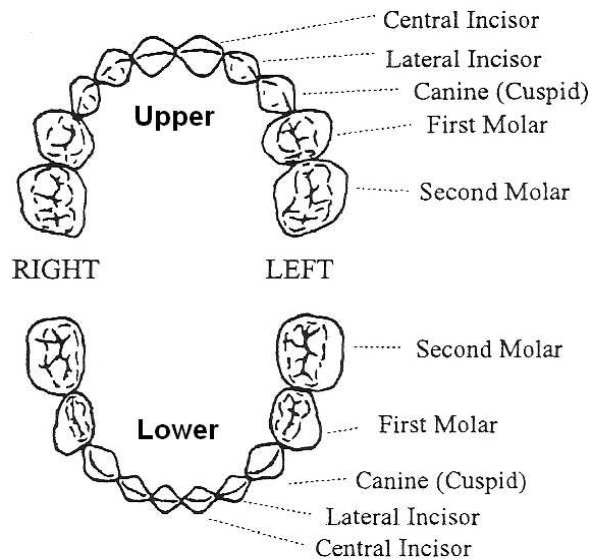


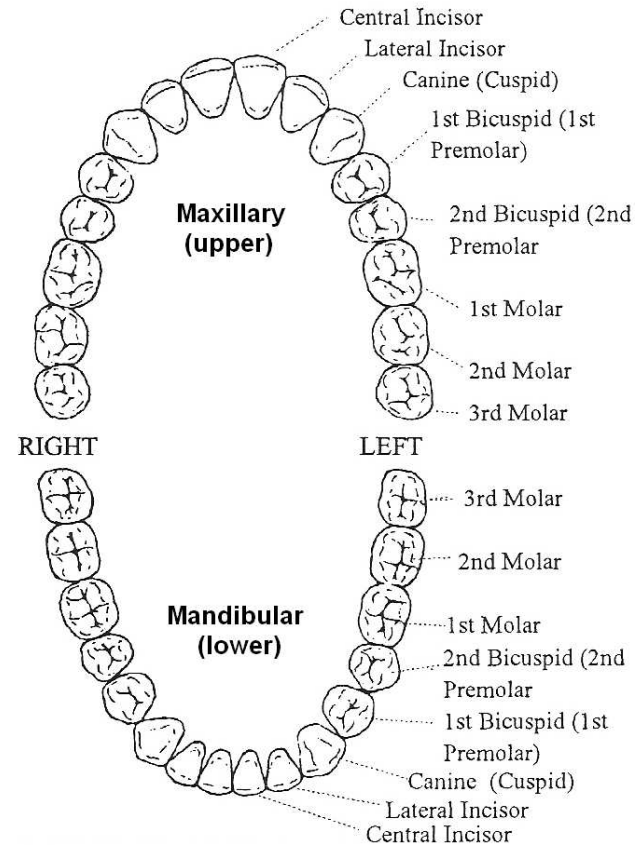
Teeth Identification by Name



If your patients could open wide, like the photo on the left, you would see teeth arranged like these diagrams

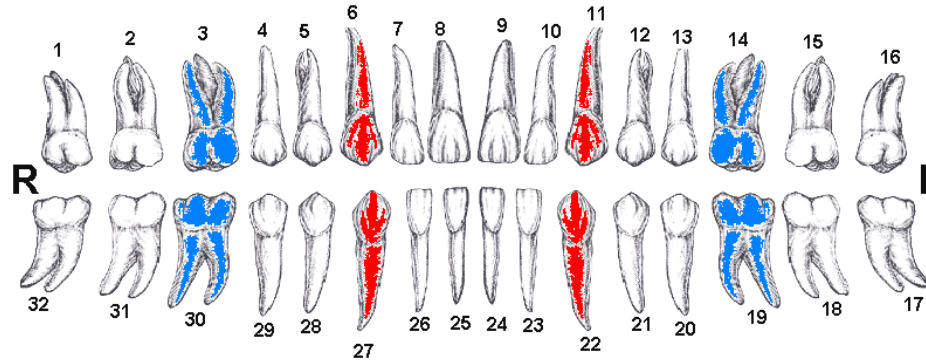
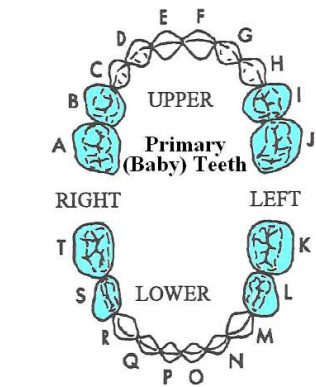
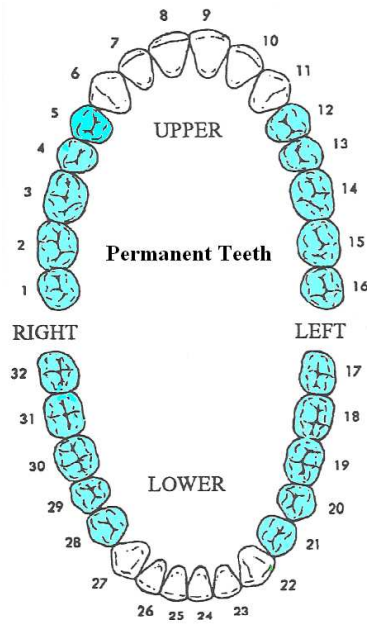


Primary (baby) teeth



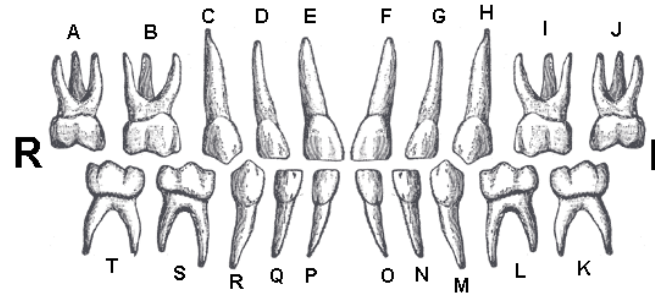
Permanent teeth

Teeth Identification by Number

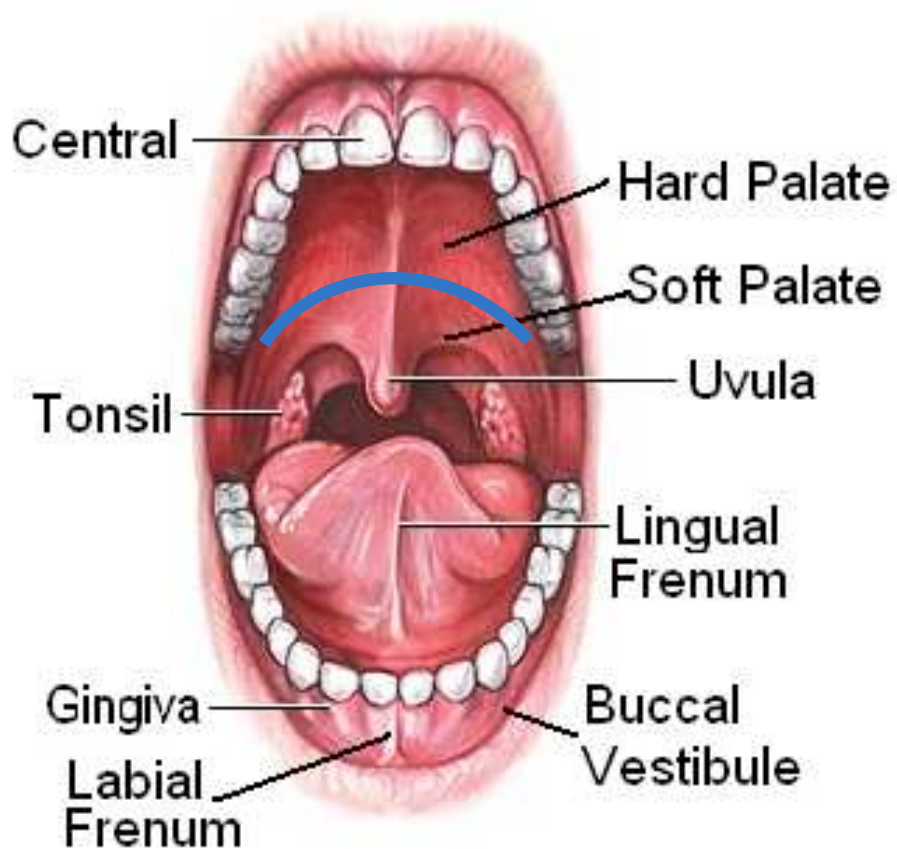


Landmark Teeth:
Learn these easy to identify **RED** & **BLUE** teeth by their number

Wisdom teeth	Anterior (teeth)	Posterior (teeth)
	Medial	Lateral



Oral Anatomy



Hard-Soft Palate Juncture:

Blue line – is where the hard palate ends (the maxillary bone) and the soft palate begins.

The *Soft Palate* is a muscle which closes off the nasal passage during swallowing.